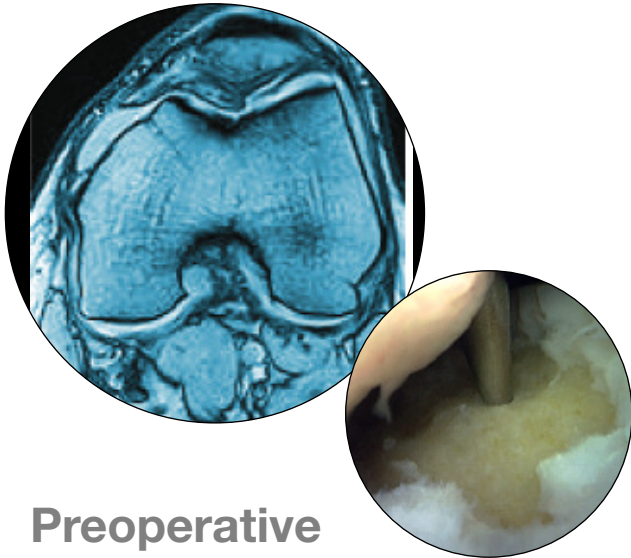




Patello-Femoral Case Study
Series Number: PF1000-104 WVM



Preoperative

Preoperative Diagnosis:

Age: 42 years old

Gender: Male

Occupation: Sales supervisor

Condition: Grade IV chondral lesion - femoral trochlea

History:

Patient had Osgood-Schlatters disease as child. He sustained a soccer injury 2 years ago.

Chief Complaint:

- Stiffness and swelling after sport
- He is able to walk but it is too painful to run

Physical Examination:

- Small effusion
- Flexion limited to 110 degrees
- PF crepitus
- Knee stable

Plan:

Resurfacing of distal PF joint with the HemiCAP® system.

Previous Surgeries

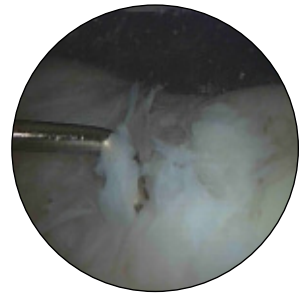Arthroscopy-Findings:

- Trochlea Grade 4 lesion
- Patella Grade 2 lesion

Debridement and Microfracture

- Extensive rehabilitation program

At 1 year post surgery, lesion appeared healed macroscopically but had mechanical failure. Patient not able to run or play soccer



Intraoperative

Straightforward procedure with no complications.

Postoperative

At 3 months, patient is pain free and has returned to running.
At 4 months, he has returned to competitive soccer.

Follow-up

At 6 months, this patient remains an active runner and athlete.
He is very happy to have had the HemiCAP® procedure.

